

The effectiveness of cream with *Centella Asiatica* and *Pinus Sylvestris* to treat scars and burns. Clinical trail

Skuteczność kremu z *Centella Asiatica* i *Pinus Sylvestris* w leczeniu blizn i oparzeń. Badanie kliniczne

**Edelisa Moredo Romo¹, Fernanda Pastrana Fundora¹, Cesar Ramírez Albajes¹,
Lisette Esteris López², Zelenkova Hana³**

¹ Educational Pediatric Hospital Juan Manuel Márquez, Havana, Cuba

² General Practitioner, Clinical-Surgical Hospital Carlos J. Finay, Havana, Cuba

³ DOST Svidnik, Private Clinic of Dermatovenereology, Slovak Republic

ABSTRACT

Background: Scars and burns are ever increasing complaints among children that turn to dermatologists to find a solution for the permanent, anaesthetic marks that they usually leave.

Aim of the study: Determine how effective Cicatrix cream (Catalysis laboratories Madrid, Spain) is to treat post-operative scars and second degree burns, and to provide patients with an alternative therapy that provides aesthetic benefits in a short period of time and has minimum adverse reactions.

Material and methods: A Phase II, open-label, controlled clinical trial was organised, that included 100 patients of both genders, aged between 0 and 18 years old, who had been diagnosed as having post-operative scars and burns at the Dermatology Service at the Pediatric Hospital Juan Manuel Márquez. Scars and burns were evaluated (colour, size) several times during the clinical trial. The sample was stratified according to the type of lesion and the gender and age groups in the stratus were homogenous. The Cicatrix cream was applied on the lesion twice a day for eight weeks.

Results: 57.1% of the burns completely disappeared after 8 weeks of the treatment and 46.7% of the scars got smaller by more than 50%. There was more than 50% improvement in colour for 95.2% of the burns and 72% of the scars. 98.7% of the patients with scars and 100% of the patients with burns responded well to the treatment. There were no adverse reactions.

Conclusions: Cicatrix is an excellent therapeutic alternative to treat these problems.

Key words: cicatrix, burns, *Centella Asiatica*, therapy

STRESZCZENIE

Wprowadzenie: Blizny i oparzenia stanowią istotny problem, z jakim zgłaszają się dzieci do dermatologa. Zmiany te pozostawiają trwałe i szpecący ślad.

Cel pracy: Określenie skuteczności kremu *Cicatrix* (Catalysis laboratoria, Madryt, Hiszpania) w leczeniu pooperacyjnych blizn i oparzenia II° stopnia. Wykazanie, że alternatywne leczenie działa w krótkim czasie i ma minimalne działania niepożądane.

Materiał i metody: Kontrolowane, otwarte badanie kliniczne II fazy objęło 100 pacjentów obu płci, w wieku od 0 do 18 lat, u których występowały pooperacyjne blizny i poparzenia. Badanie prowadzono w Poradni Dermatologicznej Szpitala Dermatologicznego im. Juana Manuela Márqueza (Dermatology Service at the Pediatric Hospital Juan Manuel Márquez). Zmiany były oceniane klinicznie (kolor, wielkość) kilka razy w czasie badania. Wyniki kliniczne wiązano z danymi demograficznymi (płeć, wiek) w celu analizy w poszczególnych kategoriach. Krem *Cicatrix* наносzono na zmiany 2x dziennie przez 8 tygodni.

Wyniki: 57,1% oparzeń ustąpiło po 8 tygodniach leczenia bez pozostawienia śladu i 46,7% blizn uległo zmniejszeniu o więcej niż 50%. W stopniu większym niż 50% stwierdzono poprawę barwy u 95,2% chorych z bliznami i u 72% z poparzeniami. 98,7% pacjentów z bliznami i 100% pacjentów z oparzeniami odpowiedziało na leczenie. Nie stwierdzono działań niepożądanych.

Wnioski: Preparat *Cicatrix* stanowi doskonałą alternatywę terapeutyczną w leczeniu blizn i oparzeń.

Słowa kluczowe: blizny, oparzenia, *Centella Asiatica*, leczenie

Introduction

In the modern world, human aesthetics is becoming increasingly more important. This is why people look for solutions to these conditions so as to improve their quality of life.

Unsightly scars are distressing, especially when they are located in very noticeable areas of the body. Scarring is the physiological tissue repair process that occurs when new connective tissue is re-generated. It can be atrophic or hypertrophic according to the degree of collagen neoformation.

There are 3 stages in the healing process: Firstly vascular or inflammatory, then granulation and thirdly the remodelling of the matrix. The latter is followed by a regression stage that can last up to two years [1].

Cutaneous scarring can have a considerable functional, aesthetic and psycho-social impact; that affects adolescents in particular. Unfortunately, at the moment there are no universally accepted instruments that could be used to assess scarring that comply with all the statistical requirements needed for widespread use [2].

With post-operative scars and those caused by burns the connective tissue usually loses its elastic properties and the *oily secretions of normal connective tissue*, the skin in the affected area is drier and rougher to touch, it's itchy and tingles.

Burns are changes in living tissue produced by different physical, chemical or biological factors whose effects can be reversible or irreversible if the tissue is completely destroyed. As our skin is our first point of contact with the outside world, it's the main organ to be affected. There are various types of burns according to their depth: first, second and third degree burns, and these are also sub-classified, what helps to establish the right medical procedure for the case in question [3]. The depth of the lesion must be carefully determined, as large burns contain different depth lesions that might vary from that of the initial lesion.

Burns are common accidents in our society, especially among children. On many occasions they are the clinical signs of child abuse and the irresponsibility of adults [4].

The long term quality and appearance of the scar and the risk of it getting infected is conditioned by how well the lesion is treated. Superficial burns or partial-thickness burns can develop into deeper third degree burns if they dry out or get infected [5].

Many different types of treatment are used for both post-operative scars and burns, these include: occlusive dressings, laser therapy, radio therapy, and cryotherapy, corrective treatment by means of a Z-plasty, using medicine such as *intralesional steroids*, interferons, certain interleukins and tacrolimus, among others [6]. Topical treatment with keratolytic agents such *kojic acid* or *glycollic acid* is also used [7]. Nevertheless, the patient and the lesion in question always have to be examined so as to prescribe the most suitable type of therapy as established by Andrades and his co-workers [8].

The Dermatology Service at the Educational Pediatric Hospital Juan Manuel Márquez was set up to treat and prevent skin diseases. A lot of its work is focused on improving people's appearance, which is part of the concept of the true state of human health, so that they can integrate into society being healthy in mind and body.

Using natural products to treat scars involves using resources that favour the healing process, prevent infections and reduce the unsightliness of the scar.

The World Health Organisation recommends using *Centella Asiatica* to promote the healing process, especially for post-operative or post-traumatic scars and also for second and third degree burns. *Centella Asiatica* stimulates the fibroblasts, which are the cells that are in charge of repairing the skin and the connective tissues.

Cream with *Centella Asiatica* and *Pinus Sylvestris* (*Cicatrix*® cream) produced by the Catalysis Laboratories in Madrid, Spain. These ac-

tive ingredients undergo a special molecular activation process making it an extremely effective product that stimulates the fibroblasts, the production of collagen (collagen types I and III), it regulates the epidermal homeostasis and modulates the chronic inflammation in the scar tissue.

For this reason a clinical trial was organised to determine how effective Cream with *Centella Asiatica* and *Pinus Sylvestris* is to treat post-operative scars and second degree burns in order to be able to provide patients with an alternative therapy that brings aesthetic benefits in a short period of time and has minimum adverse reactions.

Material and methods

Patients

A Phase II, open-label clinical trial was carried out at the Educational Pediatric Hospital Juan Manuel Márquez, in Havana, to determine how effective the product is to treat post-operative scars and epidermal burns. Patients from all over the country were assessed. The research study took place between September 2009 and September 2010. 100 patients, of both genders, aged between 0 and 18 years old, were included in the programme after having satisfied the inclusion criteria:

- patients with post-operative scars or epidermal burns,
 - aged: newborns up to 18 years old (ID card), both genders,
 - informed and signed consent.
- Patients with the following were excluded:
- showed signs of being allergic to any of the components in the product,
 - uncooperative patients,
 - uncooperative parents or guardian.

Ethics

The clinical trial was carried out pursuant to the principles established in the Helsinki Declaration. It was approved by the Ethics Committee and the Scientific Board from the Educational Pediatric Hospital Juan Manuel Márquez. All the patients signed the informed consent form agreeing to take part in the research programme. The clinical trial was registered on ClinicalTrials.gov (NCT01018589).

Organizing the clinical trial

After the initial examination, the patients who had satisfied the eligibility criteria were then included in the clinical trial. The procedure involved applying the Cream with *Centella Asiatica* and *Pinus Sylvestris* twice a day for 8 weeks.

Cream application: A fine film of the cream that covers the whole lesion is massaged on using the 2nd and 3rd fingers of the hand, according to the manufacturer's recommendations (circular movements, in a zigzag and in an 8 along the lesion). Each of the recommended movements should be repeated 10 times, as specified in the instructions for use.

Cream with *Centella Asiatica* and *Pinus Sylvestris* is available as in 30 gram tubes and it contains 1% *Centella Asiatica* and 0.5% *Pinus Sylvestris*, which are the main ingredients. The excipients included are: Abil B 8839, SK-Influx, Tego Alkanol 1618 and glycerine, among others. The active ingredients in the cream undergo a molecular activation process which makes the product highly effective to stimulate the fibroblasts, produce collagen (collagen types I and III), regulate the epidermal homeostasis and modulate the chronic inflammation in the scar tissue.

All the patients were examined at the start of the clinical trial and then every four weeks. The evaluation included a physical examination of the lesion, that was measured in centimetres with a millimetre ruler, the specific characteristics of the lesions and lo-

cation were all shown on the map of the human body and were also noted down in each patient's medical history, so that we could see if the lesion had got smaller and by how much.

The colour variation of the lesions was also evaluated, from red-violet, pink, hypochromia or hyperchromia until the lesion had completely disappeared.

Another safety variant that was assessed at each check up was whether the patient had any signs or symptoms that could be interpreted as being an adverse reaction.

Primary efficacy variable

Reduction in size of the lesion. Excellent: was considered to be when the lesions disappeared 8 weeks after having started the treatment; good: was when there was a 50% decrease in the size of the lesion, normal: when they were slightly less noticeable, having decreased in size by less than 50% and bad: when the clinical condition was the same and had not changed at all.

Secondary efficacy variables

Colour of the lesions: Good: was considered to be when the colour of the scar had faded considerably; normal: when the colour had faded slightly and bad: when it was the same colour as it was at the beginning of the clinical trial.

The final response to the treatment was considered to be excellent (very favourable) in cases where the lesions had disappeared

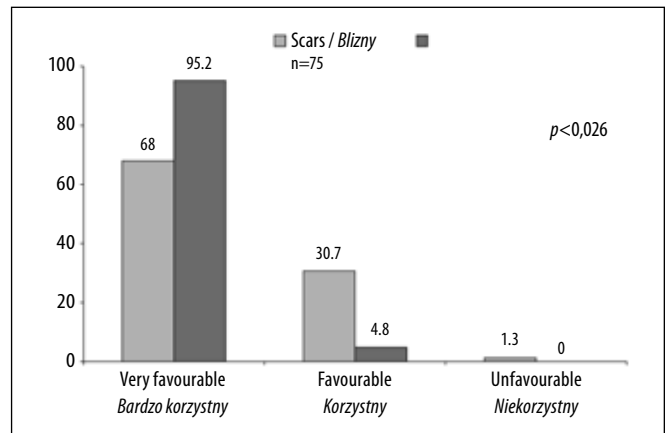


Fig. 1. Effect of the treatment according to the variables of interest
Ryc. 1. Skuteczność leczenia dla chorych z bliznami i oparzeniami

after the 8 weeks of treatment or if there was more than a 50% improvement in both the size and the colour, good: was considered to be when the colour had faded by more than 50% although the lesions had got smaller by only 25-50% or if it had decreased by 50% in size but the colour had faded by only 25-50%, normal: was when there was between a 25-50% change in both colour and size. Both responses were considered to be favourable for the treatment administered.

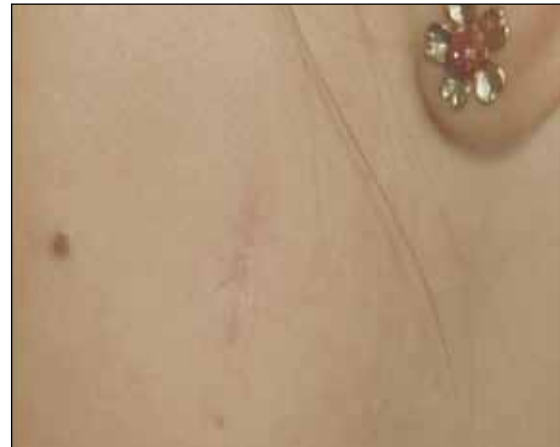
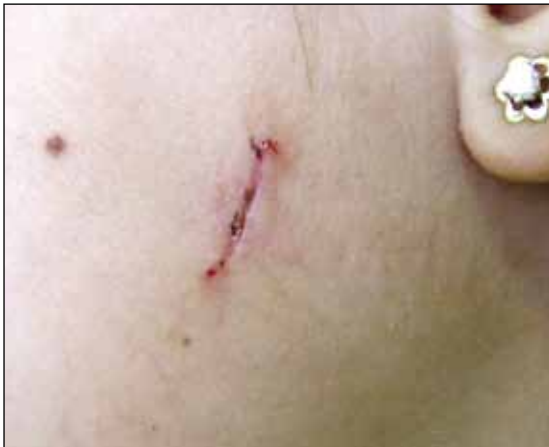
Fig. 2 and 3. Pat. No. 1. Scars treated with Cicatrix cream. Before and after the treatment
Ryc. 2 i 3. Pacjent nr 1. Blizna leczona kremem Cicatrix. Stan przed i po terapii

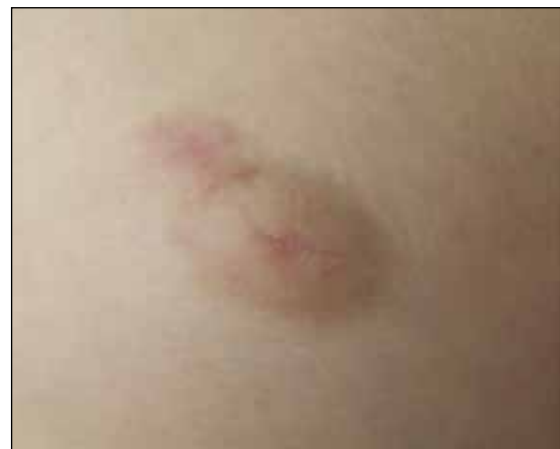
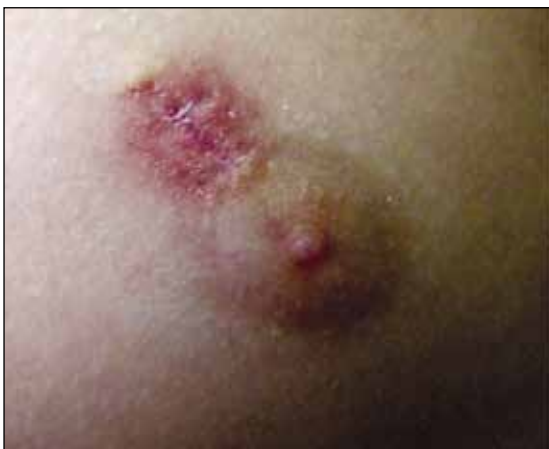
Fig. 4 and 5. Pat. No. 2. Scars treated with Cicatrix cream. Before and after the treatment
Ryc. 4 i 5. Pacjent nr 2. Blizna leczona kremem Cicatrix. Stan przed i po terapii

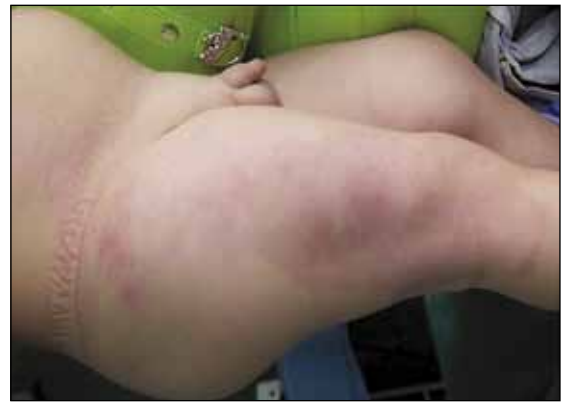
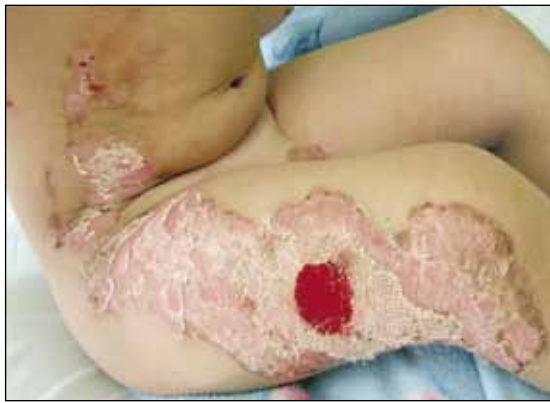
Fig. 6 and 7. Pat. No. 3. Burns treated with Cicatrix cream. Before and after the treatment
Ryc. 6 i 7. Pacjent nr 3. Miejsce po oparzeniu leczone kremem Cicatrix. Stan przed i po terapii

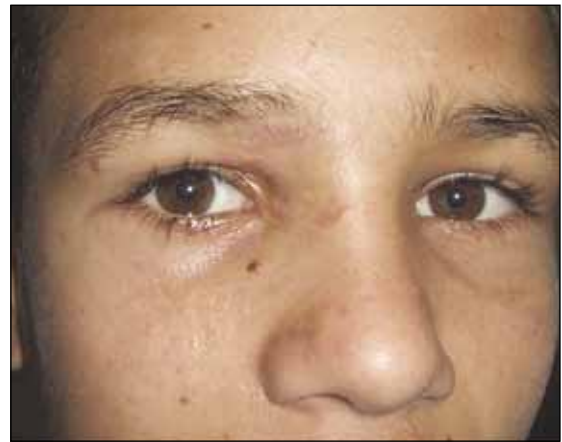
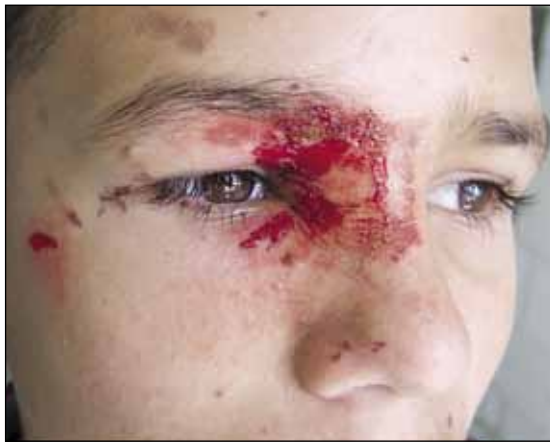
Fig. 8 and 9. Pat. No. 4. Burns treated with Cicatrix cream. Before and after the treatment
Ryc. 8 i 9. Pacjent nr 4. Miejsce po oparzeniu leczone kremem Cicatrix. Stan przed i po terapii

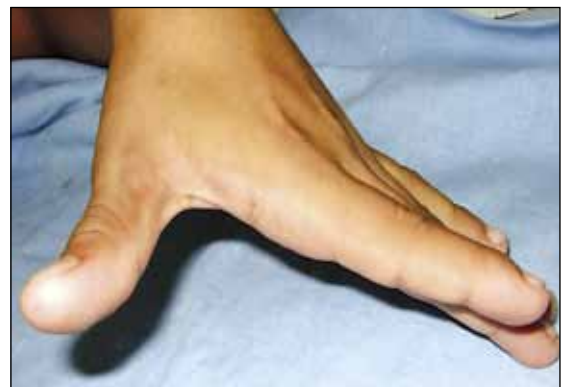
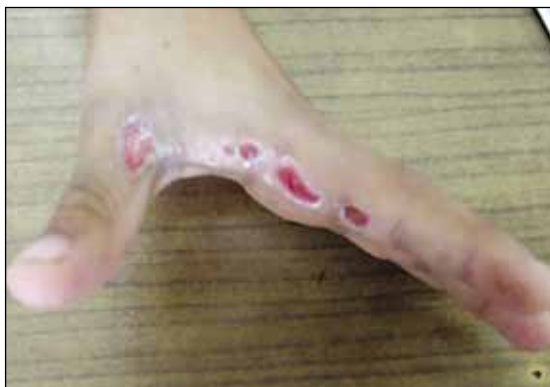
Fig. 10 and 11. Pat. No. 5. Burns treated with Cicatrix cream. Before and after the treatment
Ryc. 10 i 11. Pacjent nr 5. Miejsce po oparzeniu leczone kremem Cicatrix. Stan przed i po terapii

Bad (unfavourable): was considered to be in cases where the changes in size or the colour were less than 25%, if the lesion had stayed the same or even got worse during the treatment.

Adverse reactions: Adverse reactions were described whilst the product was being used.

Statistical analysis

The baseline characteristics of the patients were summarised by means of absolute frequencies and percentages for the *categorical*

variables; the mean and the standard deviation were used for the continuous quantitative variables. The Chi-square test was used to determine the homogeneity of the samples compared to the variables of interest. All the patients that had applied the cream at least once were included in the evaluation of the results (ITT analysis).

The evaluation of the response was summarised by means of using absolute frequencies and percentages. The Chi-squared test was used to determine the homogeneity of the samples compared to the primary and secondary efficacy variables.

Table I: Baseline characteristics of the patients according to the type of lesions

Tabela I: Dane wyjściowe pacjentów z podziałem na rodzaj zmian

Variable / Zmienne	Scars / Blizny (n=79)		Burns / Oparzenia (n=21)	
	n	(%)	n	(%)
Age / Wiek				
Younger than a year old / Młodszy niż 1. r.ż.	1	(1.3)	0	(0.0)
1-5 years old / r.ż.	8	(10.1)	4	(19.0)
6-10 years old / r.ż.	21	(26.6)	5	(23.8)
11-15 years old / r.ż.	24	(30.4)	5	(23.8)
16-18 years old / r.ż.	25	(31.6)	7	(33.3)
Gender / Płeć				
Male / Mężczyźni	26	(32.9)	10	(47.6)
Female / Kobiety	53	(67.1)	11	(52.4)
Skin colour / Barwa skóry				
White / Biała	48	(60.8)	14	(66.7)
Half-caste / Metys	24	(30.4)	5	(23.8)
Black / Murzyn	7	(8.9)	2	(9.5)

The differences between the groups were analysed using the Chi-square test ($p < 0.05$). For age, gender and skin colour ($p > 0.05$). / Różnice pomiędzy grupami były analizowane w teście Chi-kwadrat ($p < 0.05$). W odniesieniu do wieku, płci i barwy skóry ($p > 0.05$).

The safety analysis included all the patients who had used the product at least once.

The clinical trial was designed to include 100 patients and the sample was stratified according to the type of lesion (scars and burns).

All the tests carried out were two-tailed with a 5% significance level. The statistical analysis was carried out using the SPSS Inc. for Windows, version 15, Chicago, IL.

Results

Out of all the patients included in the clinical trial (n=100), 2 were excluded: One died and the other left on their own accord, so there were 98 patients (n=98) left in the sample.

79 (n=79) patients had scars and 21 patients (n=21) had burns (tab. I). With regard to gender distribution, more males had burns, to be precise 47.6% of the population, while more females had scars, namely 67.1% of the population. Caucasians predominated both groups of patients.

No significant results were obtained in any case (age, gender and skin colour) as the distribution was quite similar in each group.

With regard to the location of the lesions, 63.3% (n=50) of the scars were located on the trunk and 47.6% (n=10) of burns were located in more than one specific area.

When the behaviour of the lesion size variation was analysed, 44.3% of the patients who had scars responded excellently or well whilst 80.9% of the patients with the burns responded either well or excellently (tab. II).

As for the colour variation, 95.2% of patients with burns and 72% with scars responded well (tab. II).

As for the lesion size variation and that of the colour with regard to the final response to the treatment, 57.1% of the patients with burns responded excellently to the treatment whilst 57.3% of those with scars responded well, producing a significance level of $p < 0.001$ (tab. II).

On assessing the behaviour of the variables established in both groups that used cream with *Centella Asiatica* and *Pinus Sylvestris* to determine its effectiveness, the results were positive and very positive for 100% of the patients with burns and for 98.7% of the pa-

Table II: Response evaluation according to the variation in response

Tabela II: Ocena skuteczności w zależności od rodzaju ocenianej cechy

Variable Zmienne	Scars / Blizny (n=75)		Burns / Oparzenia (n=21)	
	n	(%)	n	(%)
RSVT*				
Excellent / Doskonaly	8	(10.7)	12	(57.1)
Good / Dobry	27	(36.0)	5	(23.8)
Normal / Normalny	38	(50.7)	4	(19.0)
Bad / Zly	2	(2.7)	0	(0.0)
RSVC**				
Good / Dobry	54	(72.0)	20	(95.2)
Normal / Normalny	21	(28.0)	1	(4.8)
Bad / Zly	0	(0.0)	0	(0.0)
FR*				
Excellent / Doskonaly	8	(10.7)	12	(57.1)
Good / Dobry	43	(57.3)	8	(38.1)
Normal / Normalny	23	(30.7)	1	(4.8)
Bad / Zly	1	(1.3)	0	(0.0)

RSVT – Response according to the size variation of the lesion / Odpowiedź wyrażona zmianą wielkości zmiany; RSVC – Response according to the colour variation of the lesion / Odpowiedź wyrażona zmianą barwy zmiany; FR – Final Response / Ostateczna odpowiedź; The differences between groups were analysed using the Chi-square test ($p < 0.05$). / Różnice pomiędzy grupami były analizowane w teście Chi-kwadrat ($p < 0.05$).

* $p < 0.001$

** $p = 0.05$

tients with scars, with a significance level of $p < 0.026$ (fig. 2). Very favourable included those who had no trace of the lesion at the end of the treatment period and cases where there was more than a 50% improvement in both size and colour, favourable was considered to be those whose improvement in colour and size was between 25 and 50%, and the unfavourable group consisted of cases

where the improvement was hardly noticeable (less than 25% improvement) or where the lesion had even got worse.

No adverse reactions were reported whilst the groups under analysis were being treated with the Cream with *Centella Asiatica* and *Pinus Sylvestris*. One interesting finding was that the half-caste and black patients who had burns with *residual* hyperchromic *macules had blotchy skin pigmentation* until most of the normal colour had been restored. Progress was very different in those cases that had had untreated keloids or hypertrophic scars in the past compared to those who had had the aforementioned disorders treated. In the latter cases, they were seen to be smoother, flatter and aesthetically more acceptable than the former untreated cases.

Photos were taken of each patient at the beginning and at the end of the treatment (Annex 1 and 2).

Discussion

The biggest age group of patients in our clinical trial sample is related to their concern for their physical and aesthetic appearance, which is normally the case of adolescents. The other age groups had homogenous behaviour.

Scars were more common among the female patients whilst burns were more common among the males. This might be related to the fact that more females seek help to correct or improve their appearance than males, which means that our criteria coincides with that of other studies carried out in Cuba that highlight the fact that there is a greater female demand for treatment to improve skin problems and facial blemishes [6].

The fact there were more Caucasians in the sample than any other skin colour could be related to the fact that, according to demographic reports from the country written in the last few years, the Cuban population is predominated by Caucasians and half-castes. We do however agree with other Cuban authors that this point is of no real importance when analysing *disorders caused by accidents* [9].

In our sample, the scars were mainly located on the trunk whilst the burns were located in more than one area. This might be due to the fact that the patients that had been included in the clinical trial were sent by the dermatology service, where surgery for melanocytic nevus or moles is very common and as the trunk is such a large area this is where these lesions are often located.

When the Cicatrix cream was applied to the scars, they were seen to disappear completely or decrease in size by half on a considerable number of patients. This finding can be compared to another study carried out in Venezuela in which *Centella Asiatica* was applied directly on the hypertrophic scars and keloids and had very good results [10]. Results from Zelenková in Slovakia were also very similar to ours [11, 12]. Even in the cases where there was only a slight reduction in size or colour of the scar, the affected area was smooth.

Lesions were seen to completely disappear and the normal skin colour was preserved in a large number of the patients with burns. In some cases, there was repigmentation in the affected area in which the original skin colour tended to come back. Similar results were found when hydrogel, biosynthetic and antimicrobial dressings were used according to Wasiak Jason and co-workers [13], in which aesthetic results were obtained in a shorter period of time when these dressings were used to treat the burns.

By using cream with *Centella Asiatica* and *Pinus Sylvestris* considerable number of patients managed to improve the clinical appearance of their scars and tone down the colour of the lesions so that they were more aesthetically acceptable. We think this is directly related to the modulation effect of the cream on the inflammation in the scar tissue. This result can be compared to another similar study carried out in Europe [10, 11], where positive changes were observed in the hypertrophic scars and the keloids when this

cream is used and in the results obtained by Draelos [14] concerning the aesthetic appearance of the scars after a natural product gel had been applied.

On evaluating the overall effect of the cream with *Centella Asiatica* and *Pinus Sylvestris* on the post-operative scars and epidermal burns according to the variables of interest, both groups were seen to respond extremely well to the treatment, which we believe could, to a great extent, be related to the stabilising effect of the collagen fibres and the changes in the fibroblasts caused by *Centella Asiatica* combined with the anti-inflammatory, antiseptic and healing effect of the *Pinus Sylvestris*. No adverse effects were detected in any of the patients.

Conclusions

In view of the aforementioned, we conclude that cream with *Centella Asiatica* and *Pinus Sylvestris* is an excellent alternative to treat post-operative scars and epidermal burns, it can be self-applied, it's easy to use and there are hardly any adverse reactions, if any.

We recommend carrying out clinical trials in which this cream, whose main ingredients are *Centella Asiatica* and *Pinus Sylvestris*, is used to heal skin burns and scars by secondary intention.

References

1. Kirsner R. *Wound healing*. In: Bologna J, ed. *Dermatology*. 1st ed. Spain: Mosby; 2003;2. p.2007-2018.
2. Andrades P, Benitez S, Prado A. *Recomendaciones para el manejo de cicatrices hipertróficas y queloides*. Rev. Chilena de Cirugía. 2006;58:78-88.
3. Benain F. *Notas del ayer: Opinión personal sobre una clasificación uniforme para la profundidad de las quemaduras*. Rev. Argentina de Quemadura. 2000;15:15-16.
4. Cohen BA. *Dermatitis artefacta*. Cap. 10 en: *Pediatrics Dermatology*. 3th ed. New York: Elsevier, Inc. 2008. p.258-270.
5. Merino JE, Caballero AM. *Opciones terapéuticas para cicatrices queloides e hipertróficas*. Rev Cent Dermatol Pascua. 2007;16:28-35.
6. Moredo E, Pastrana FM, Ramírez CR; Rodríguez G. *Tratamiento del acné con ácido glicirricínico*. Folia Dermatológica Cubana. (Online magazine). 2008;2:12-14. Available: <http://bvs.sld.cu/revistas/fdc/indice.html>.
7. Zurada JM, Kriegel D, Davis IC. *Topical treatments for hypertrophic scars*. J Am Acad Dermatol. 2006; 55:1024-1031.
8. Andrades P, Benitez S, Prado A. *Recomendaciones para el manejo de cicatrices hipertróficas y queloides*. Rev Chilena de Cirugía. 2006;18:78-88.
9. Martínez FAJ, Fernández D, Ivonne E. *Is race an useful criterion in medical practice?* Rev Cubana Med Gen Integr [Online magazine]. 2006 [citado 2011 Mar 15]; 22. Available: http://scielo.sld.cu/scielo.php?script=sci_arttext&pid=S0864-21252006000100006&lng=es.
10. Beleña RA, Lacovara DS. *Ensayo experimental con Centella Asiática intralesional en queloides y cicatrices hipertróficas*. Derm Venez. 1993;31:19-22.
11. Zelenková H. *Pilot study to verify the effects of Cicatrix® cream application (CATALYSIS, S. L. Madrid) in patients with keloid and hypertrophic scars. Final report*. Madrid April 2007
12. Zelenkova H, Stracenská J. *Novel method of Keloid scars conservative therapy employing a preparation containing Centenela Asiatica and Pinus Sylvestris*. EADV Spring symposium Bucharest. April 23-26, 2009.
13. Wasiak J, Clealand H, Campbell F. *Apósitos para las quemaduras superficiales y de espesor parcial (Revisión Cochrane traducida)*. In: La Biblioteca Cochrane Plus, 2008(4). Oxford: Update Software Ltd. Available: <http://www.update-software.com>. On 24th May 2010.
14. Draelos, ZD. *The ability of onion extract gel to improve the cosmetic appearance of postsurgical scars*. J Cosmet Dermatol. 2008;7:101-104.

Received: 2012.07.01. Approved: 2012.09.02.

Conflict of interests: none declared

Address for correspondence:

Dr. Edelisa Moredo Romo

e-mail: edelisa.moredo@infomed.sld.cu